



Welcome...

Welcome to the Winter edition of our newsletter, designed to keep you up to date with what's happening in the veterinary world!

Garden Birds

Garden birds are extremely vulnerable during the winter months and providing food and fresh water is one of the most helpful things you can do for them. During cold winter nights birds can sometimes lose 10% of their body weight just keeping warm, which means they quickly need to find food the following day, just to replenish their reserves for the cold night ahead. Prolonged cold spells can lead to a very high mortality rate in birds.



Hanging feeders suspended from trees or poles are an easy way of feeding birds. Seed feeders are tubular transparent containers with holes through which the birds are able to access

a high calorie seed mix, whilst nut feeders are made of steel mesh and are ideal for unsalted peanuts. Bird tables can be stocked with seed mixes and a selection of household scraps such as cooked potato, cake crumbs and soft fruit. It is also important to ensure that birds have access to fresh and not frozen water since many birds die in severe weather due to dehydration. A suspended water dish is a good way of achieving this and, if it is very cold, use tepid water. Further information on caring for garden birds can be found online at www.rspb.org.uk

The benefits of having your pet neutered!

DID you know that in addition to preventing unwanted pregnancies, there are many other health and behavioural benefits to having your pet neutered and we've outlined some of these below for you.

Dogs: In female dogs, heat periods (or seasons) usually occur twice a year and last about three weeks. During this time your dog will be receptive to the advances of un-neutered male dogs in your area. In both sexes, the urge to mate can lead to roaming, with the associated risk of becoming permanently lost, getting involved in fights or, worse still, being injured in a road accident.

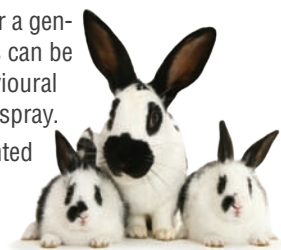


Cats: Female cats come into heat as often as every two weeks during the breeding season (in the spring and summer months) and will endlessly try to escape to mate with local tom cats. Male (tom) cats, particularly if not neutered, will mark their territory by "spraying" objects inside and outside your house with strong smelling urine. In addition, they are frequently involved in fights, resulting in bite injuries and the risk of acquiring deadly viral infections. Sexual contact can also lead to transmission of deadly viruses as well.

In females, neutering (termed spaying), involves removing the ovaries and uterus under a general anaesthetic. As well as preventing seasons and unwanted pregnancies, spaying also removes the possibility of life-threatening uterine infections. Additionally, it also greatly reduces the risk of developing potentially fatal mammary tumours later in life.

In males, neutering (termed castration), involves removal of both testes under a general anaesthetic. Neutering makes male pets less likely to stray, and in dogs can be of help in controlling excessive sexual drive and with certain types of behavioural problems. Neutered male cats are far less likely to get into fights and urine spray.

Rabbits may also benefit from being neutered. As well as preventing unwanted pregnancies, they are generally calmer and can be more easily kept in social groups without fighting. Additionally, spaying removes the risk of uterine cancer which is common in older unspayed females.



If you would like more information on neutering, or to book an operation, please give us a call!

Ouch! Could my cat have tooth ache?



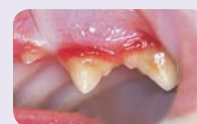over the age of three may have some form of dental disease!

Gum disease is a common problem in cats, dogs and humans, and is caused by the accumulation of plaque bacteria on the surface of the teeth. This leads to reddened gums and, if untreated, often results in tooth loss.

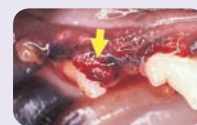Tooth resorptive lesions are fairly common in cats (but not dogs) and are usually found around the gum line. Here the tooth is progressively destroyed leading to exposure of the nerve. These are generally extremely painful, although cats may show no obvious outwards sign of pain.

Regular dental examinations can be of great help in identifying dental disease *before* it becomes a serious and painful problem. Please ask us for further information on dental care for your pets!

APPEARANCES can be deceptive! It's a fact that many cats (and dogs for that matter) live with the pain of long term dental problems, *without* showing any obvious outward signs of tooth ache. In fact, recent surveys have shown that as many as 70% of cats and 80% of dogs



Gum disease (reddened gum margins) is a sign of an unhealthy mouth and can lead to tooth loss.



Tooth Resorptive Lesion (arrowed). The tooth is progressively destroyed.

Ear Disease – is your pet affected?



DO you notice your pets scratching their ears? Are there any signs of redness or discharge? Unlike the condition in people where “earaches” commonly involve the middle and inner ear, most ear problems in pets occur in the outer or external ear canals (see diagram right).

The ear is protected externally by a pinna (or flap). Sound is collected by the pinna and then travels down the narrow external ear canal to the ear drum, where it passes onto the middle and inner ear.

In the healthy ear, the opening to the external ear canal is lined with smooth pink (or pigmented) skin, with no evidence of any redness or discharge.

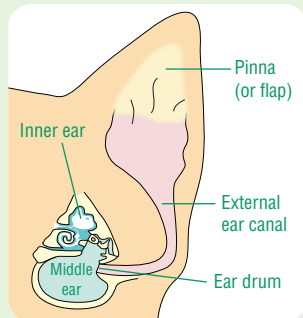
As mentioned above, most ear problems seen in pets occur in the *external ear canal* – a condition called **otitis externa** (sometimes called canker). Signs of otitis externa commonly include ear rubbing, head shaking and reddened irritated skin lining the external ear canal. Additionally there is often a discharge.

So what causes it? Virtually all otitis externa is triggered by an *underlying* cause and these can include:

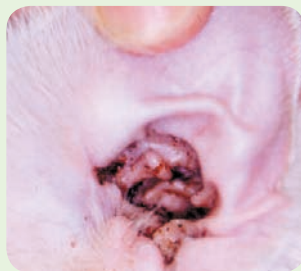- Ear mites (*Otodectes cynotis*) are a tiny spider like parasitic mite that infect the ears of dogs and cats causing irritation and a crusty brown discharge.
- Foreign bodies – such as the **grass awns** of the meadow grasses are a particular problem in the summer months and can easily get stuck right down by the ear drum – see photo right.
- Localised allergies affecting the skin lining the external ear canal are another common cause. These are often part of a more generalised allergic skin condition also affecting other body areas.

In many instances of ear problems, scratching the affected area leads to *opportunistic* bacterial and fungal infections colonising the ear canal which can both obscure diagnosis of the underlying cause and, worse still, complicate treatment of the otitis externa.

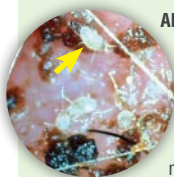In common with many conditions, the key to success with otitis externa is *early diagnosis and treatment*. If your pet is showing *any* of the symptoms described above, please bring him in for a thorough examination since the sooner we can start treatment the better!



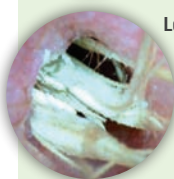
The ear in cross section. Most ear problems occur in the external ear canal



Above: Otitis externa in a cat with ear mites (*Otodectes cynotis*) with a typical crusty brown discharge.



Left: close up of ear mites (yellow arrow)



Left: Photo of a grass awn lodged at the base of the external ear canal. Pets with trapped grass awns will present with severe head shaking.

Winter Worries!

Brrrr – it's hard to believe that autumn is over and we have the long cold winter months ahead of us! With this in mind we've put together some seasonal tips to keep your pets fit and healthy.

Arthritis: Look out for any limps and difficulties in rising after rest; these are signs that your pet may have some joint stiffness, often made worse by wintry weather. If your pet is showing any signs of stiffness or limping, please get in touch.

Can you pinch an inch? With many pets spending more time indoors during the winter months – they are getting less exercise and need correspondingly less food. Keep an eye out for any weight gain since excess weight can cause a range of health problems including heart disease, diabetes and can also significantly worsen arthritis.

Winter flea alert! With modern central heating, fleas are no longer a seasonal summer problem! **Spot-on treatments** are ideal for treating your *pets*, whilst **larvicidal house sprays** can be used to prevent fleas developing in your home.

Christmas decorations such as ribbon and tinsel are very attractive to pets and, if swallowed, may lead to an intestinal blockage. Similarly make sure that turkey carcasses are safely disposed of.

Chocolate is often found in abundance at this time of year and poses a significant hazard to dogs.

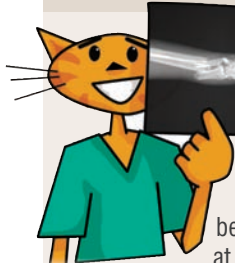In general the higher the cocoa content the more toxic the chocolate. **Grapes, raisins and sultanas** are also now known to be toxic to dogs, so beware of your dog wolfing down the leftover Christmas pudding or Christmas cake!

Remember also that **lilies** pose a risk to cats, with all parts of the plant being toxic.

Outdoor pets: The winter months can be very tough for rabbits and guinea pigs. It is important to ensure that their hutches are warm, dry and clean and have plenty of bedding. Water bottles should be checked regularly to ensure they are not frozen.



X-Ray Vision!

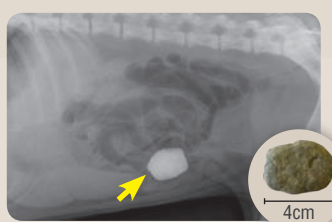


X-RAYS are one of a number of tests we can use to help us make a diagnosis following a physical examination of your pet.

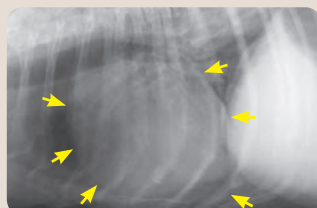
Although X-rays show up bones best of all (and are ideal for looking at broken bones and arthritic joints)

they are also useful for looking at the size, shape, and consistency of a number of organs such as the heart, lungs, stomach, liver, spleen, kidneys and bladder.

The cases on the right illustrate some of the ways that we use x-rays in veterinary practice. As always, **pet insurance** is also a really good idea to ensure that cost doesn't become the limiting factor in diagnosis and treatment of any problems discovered.



Abdominal x-ray of a dog suspected of swallowing a large pebble, which was removed following surgery (see inset).



Chest radiograph of a dog with an enlarged (ball shaped) heart which is arrowed

